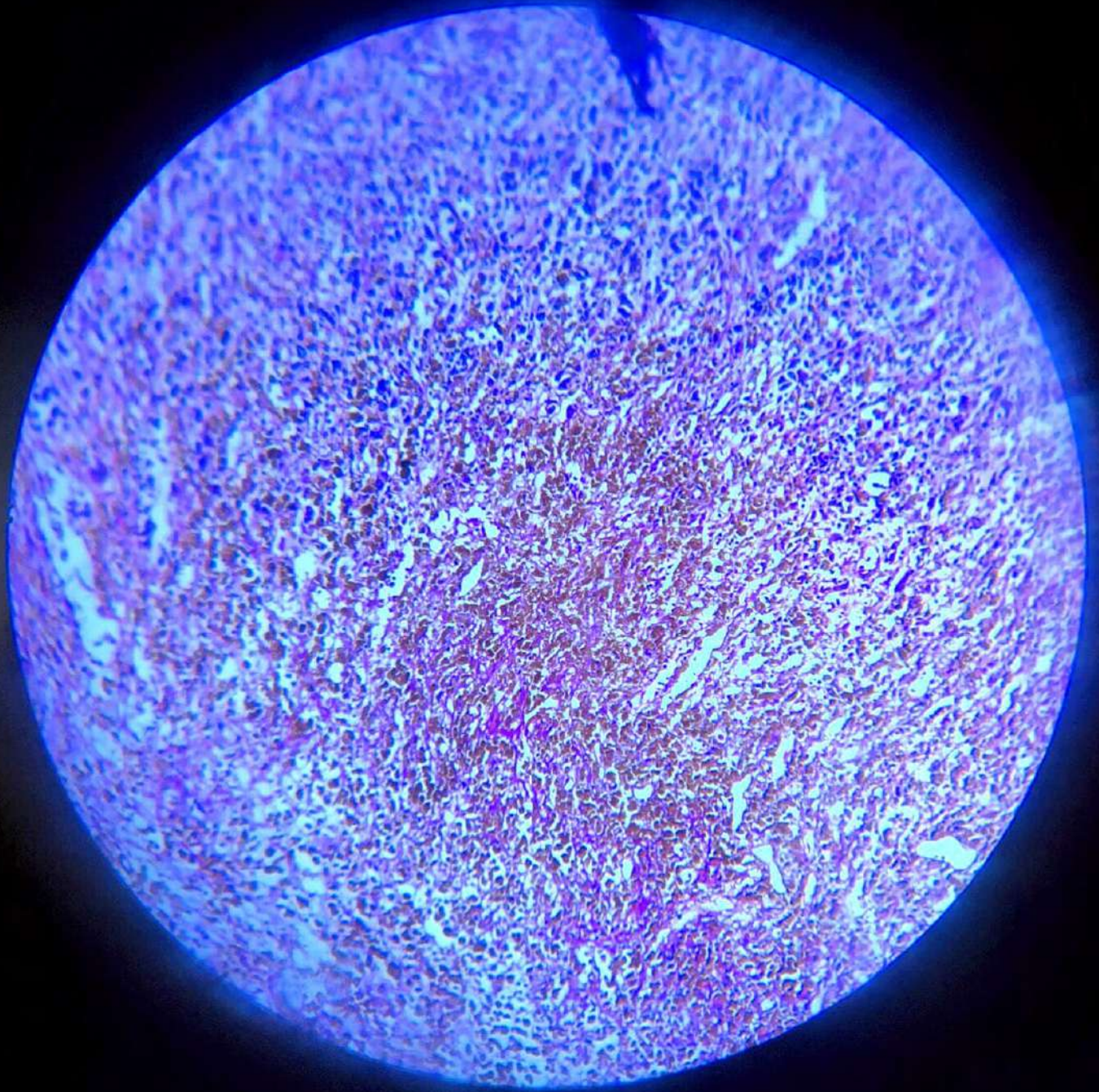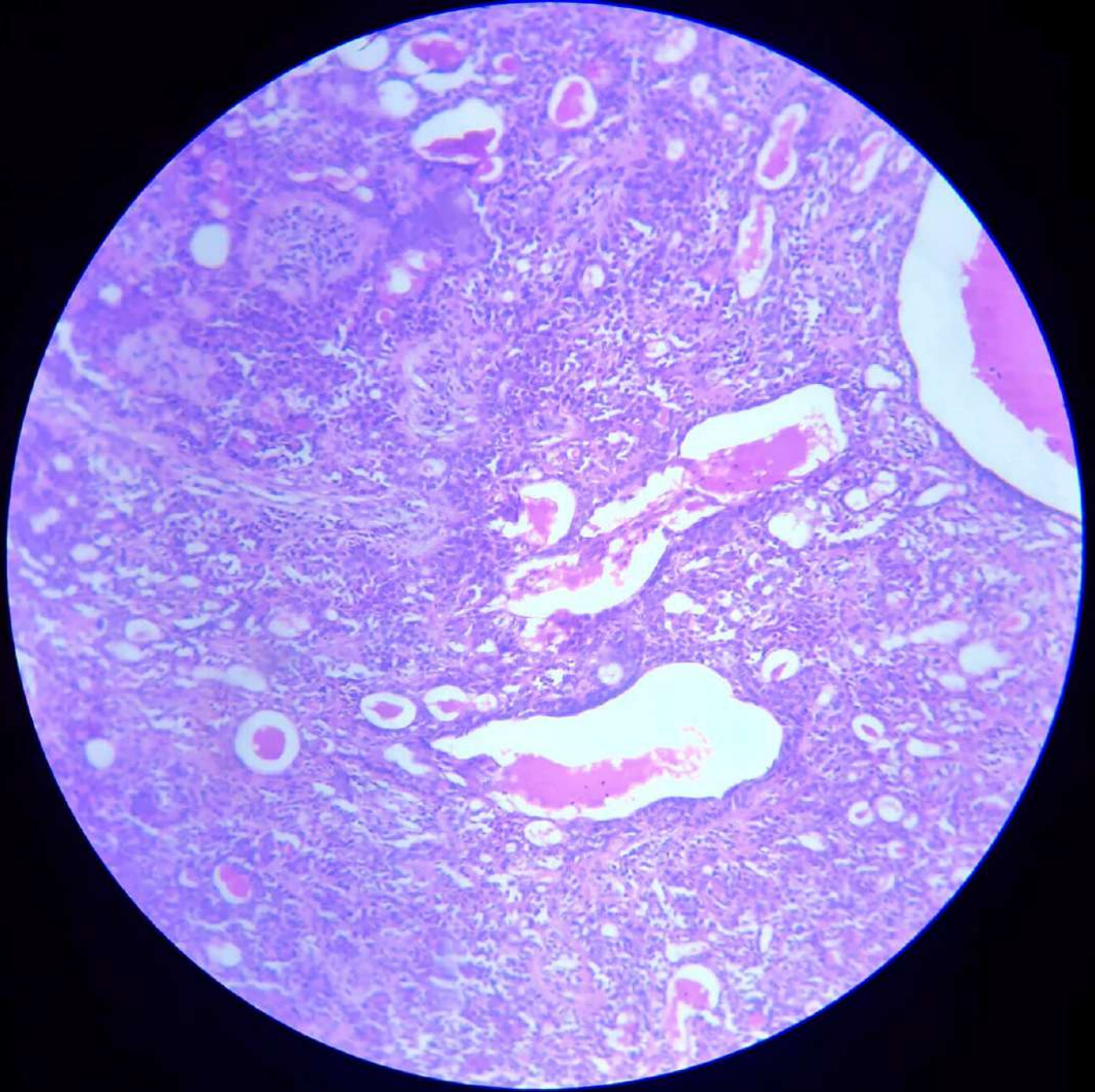
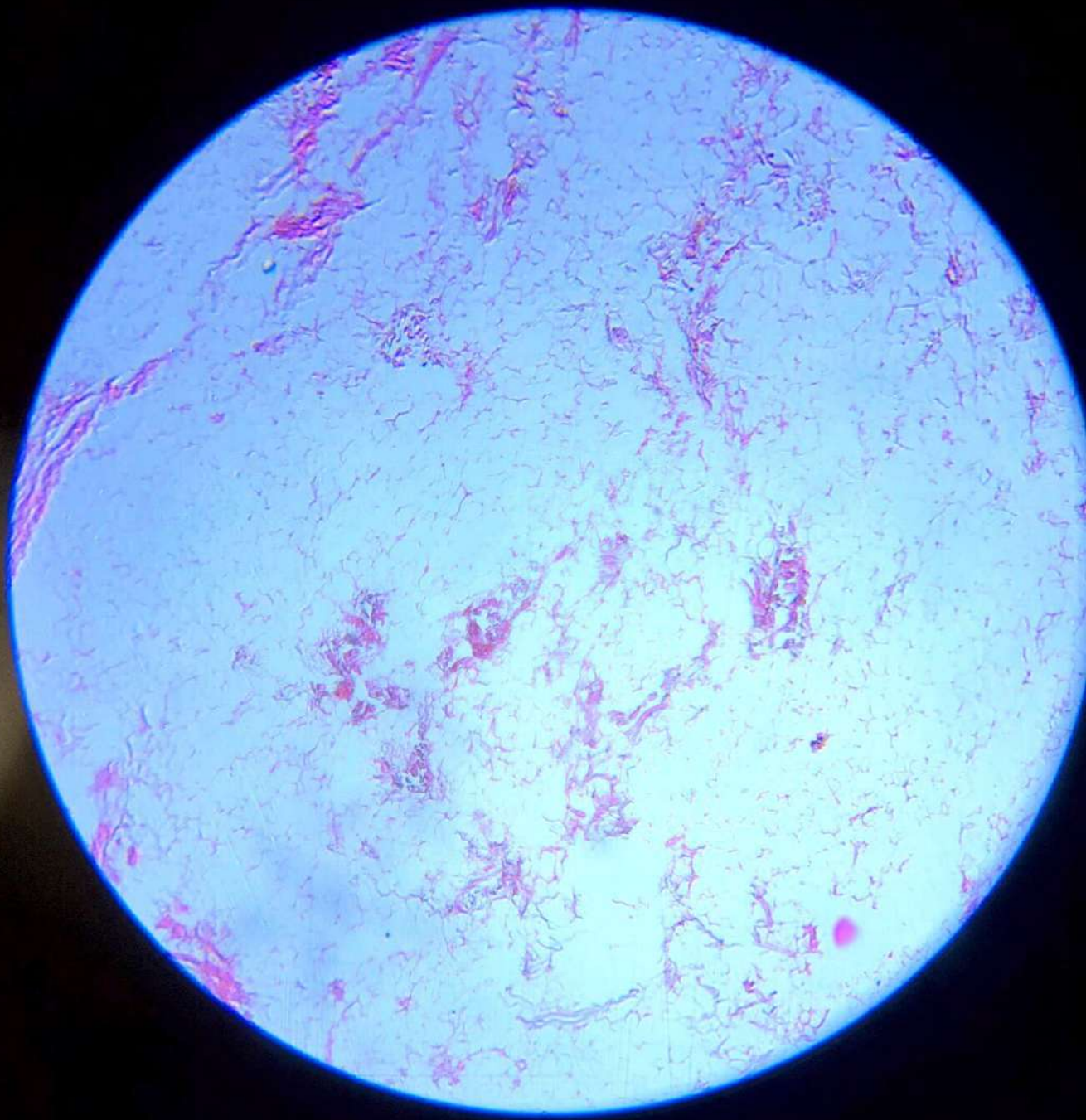


**Malignant  
Melanoma**

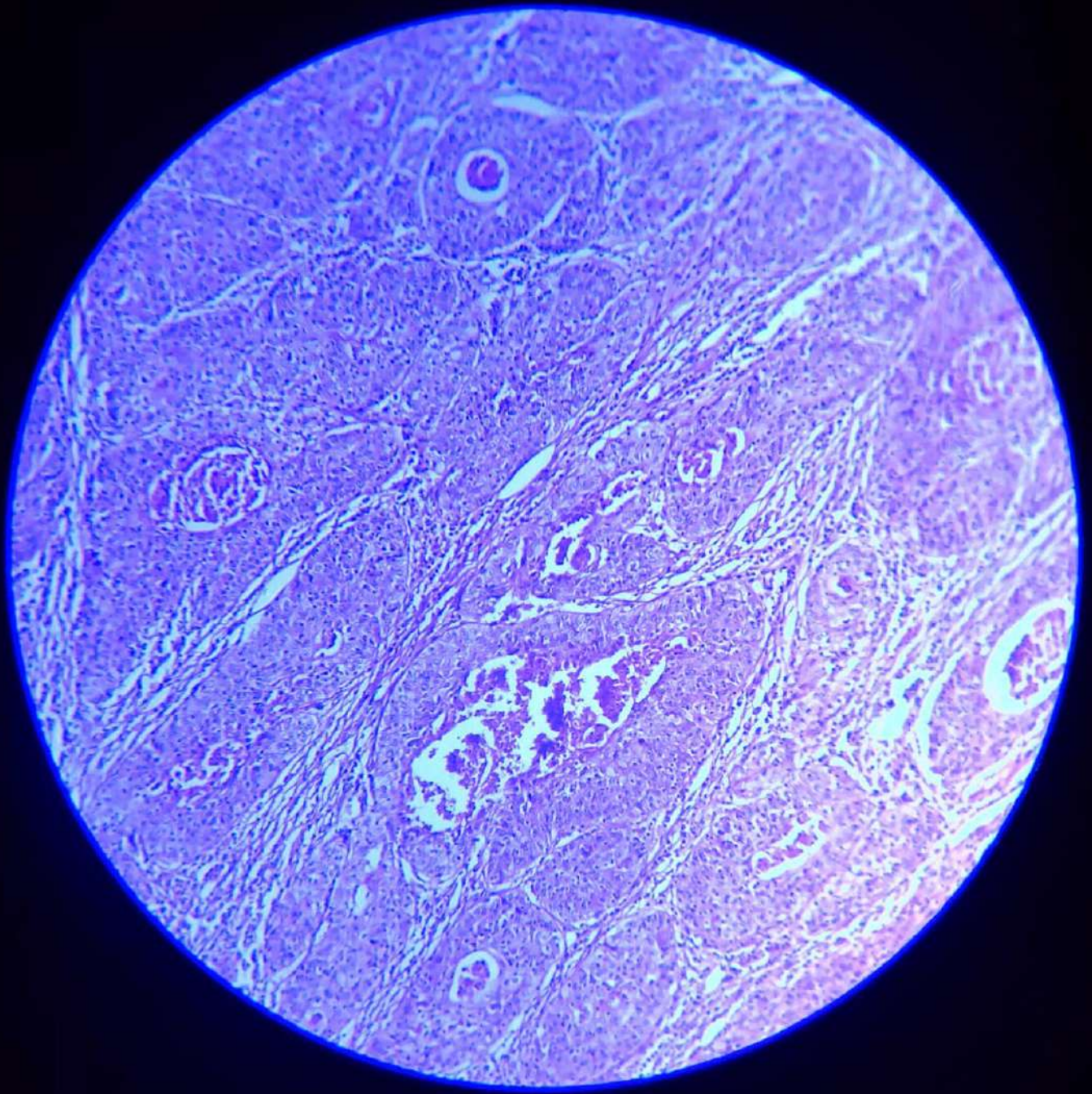


Pleomorphic Adenoma

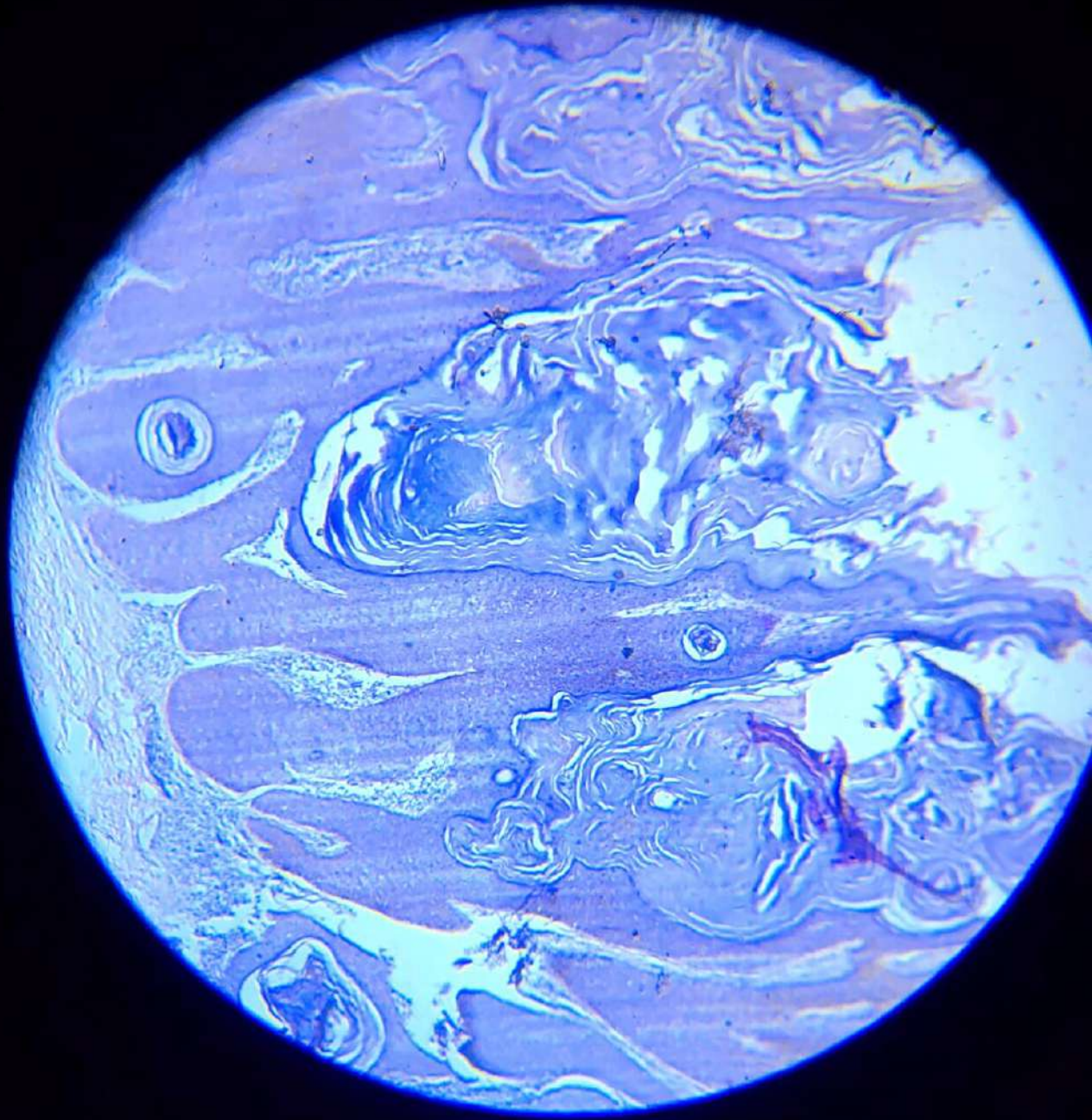


Lipoma

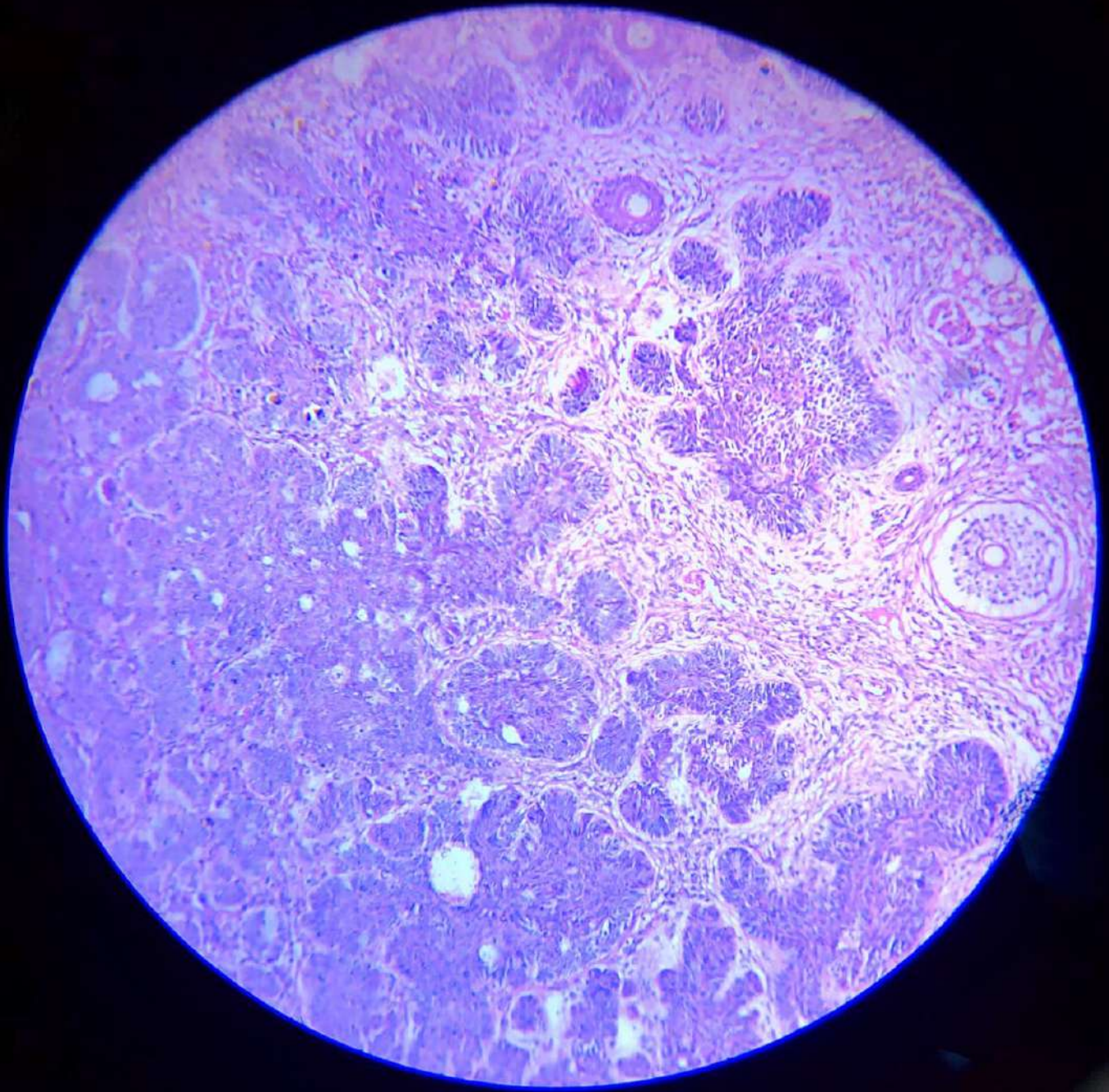




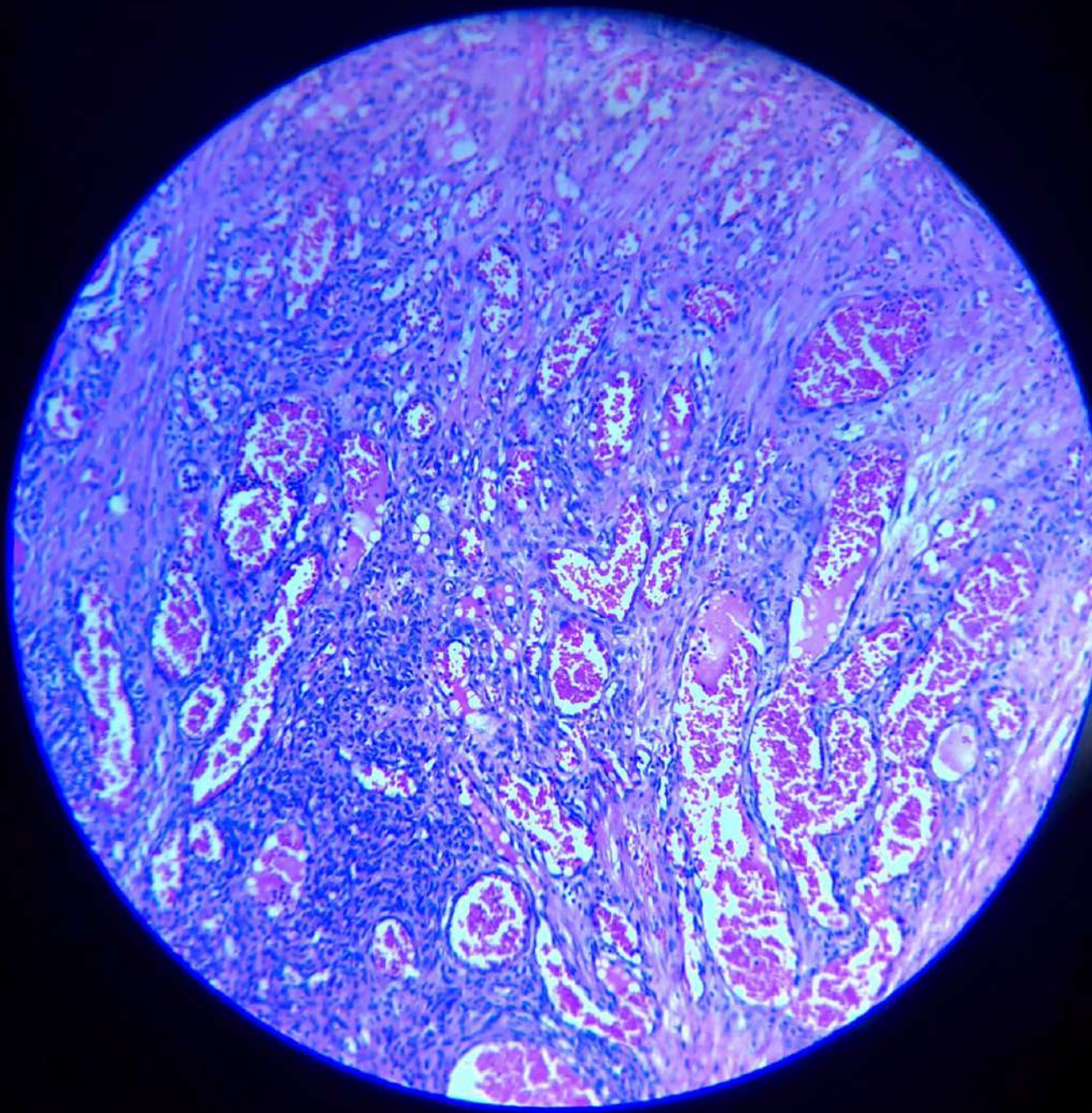
Squamous cell carcinoma



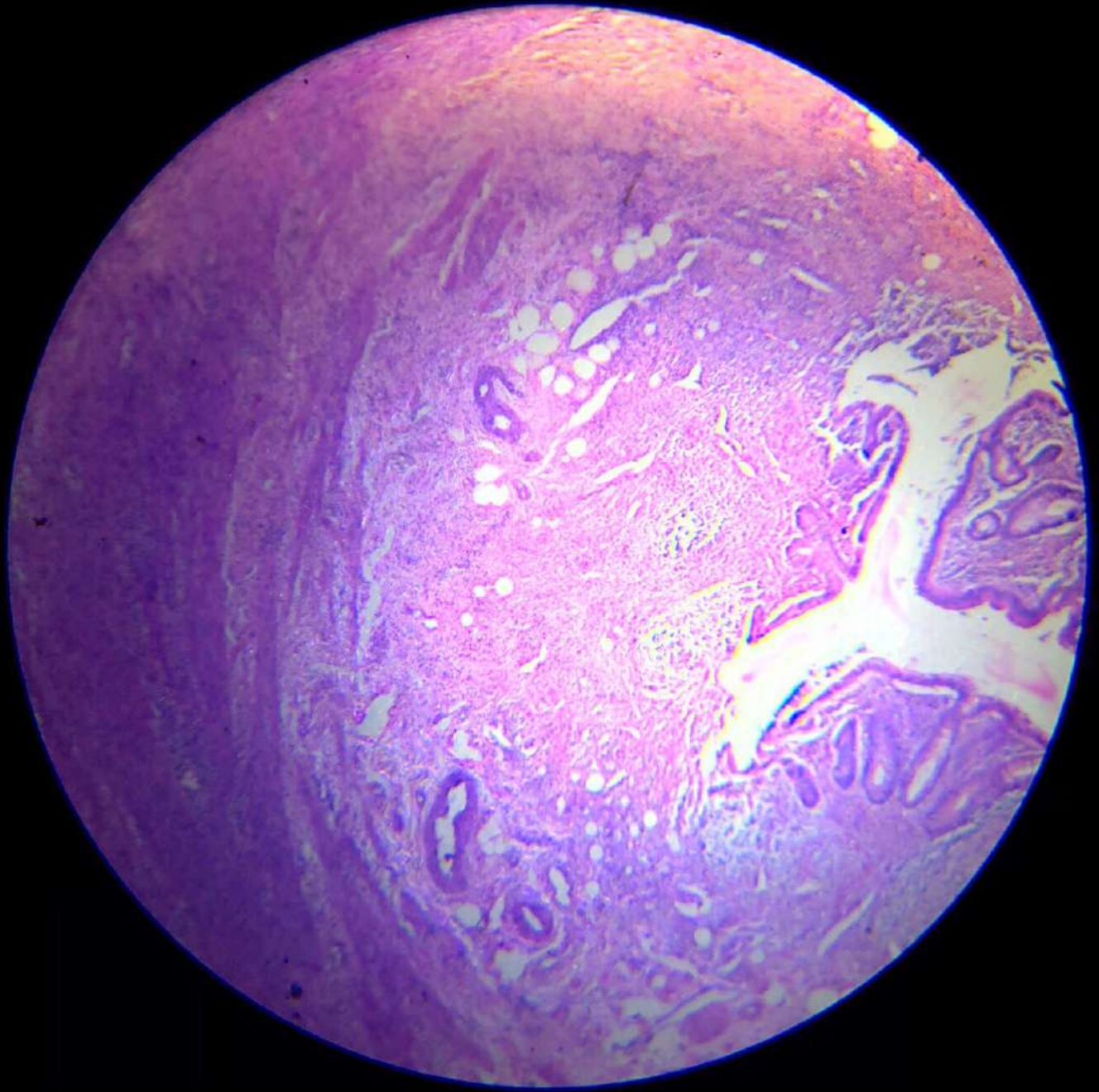
Squamous cell papilloma



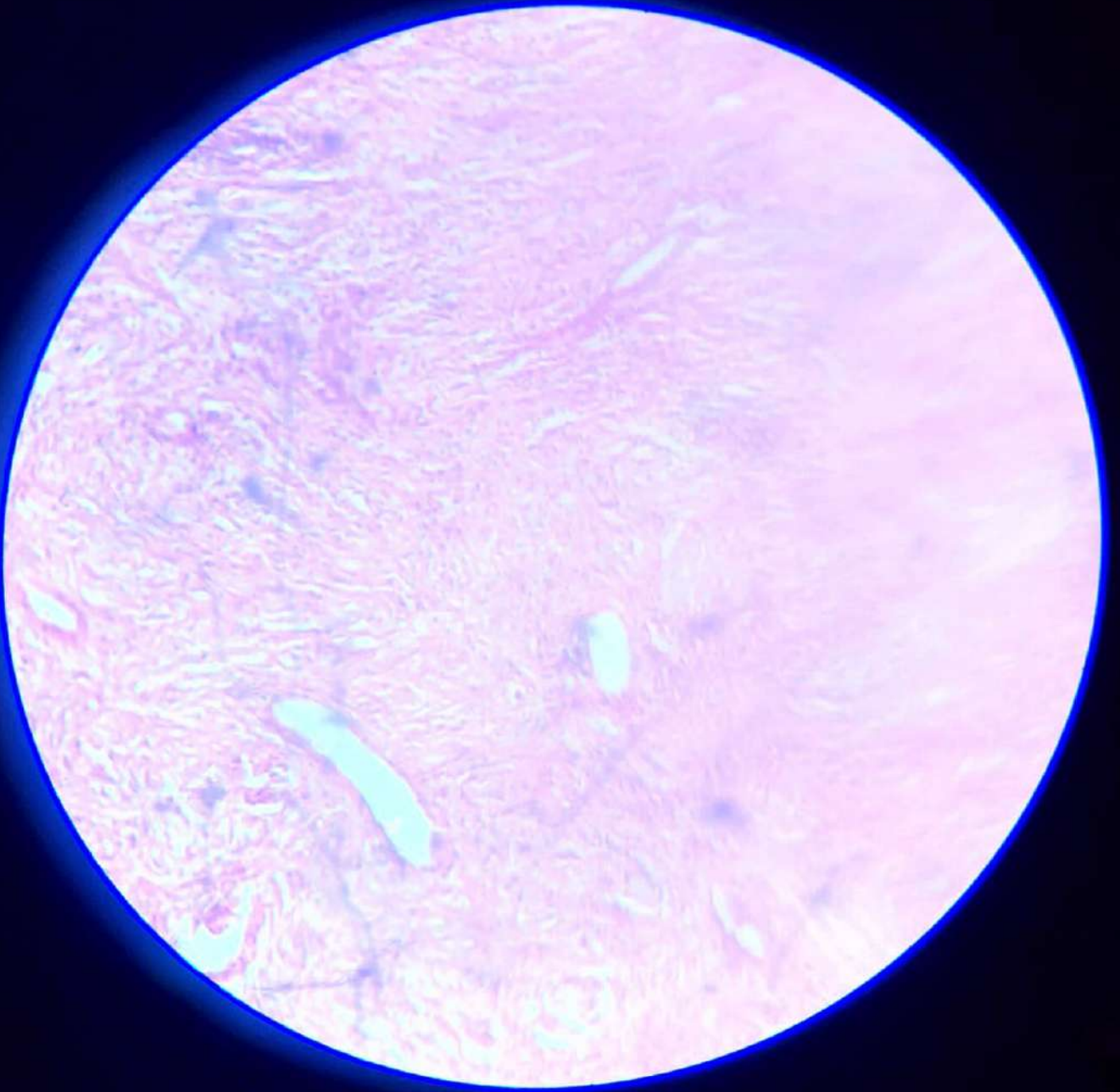
Basal cell carcinoma



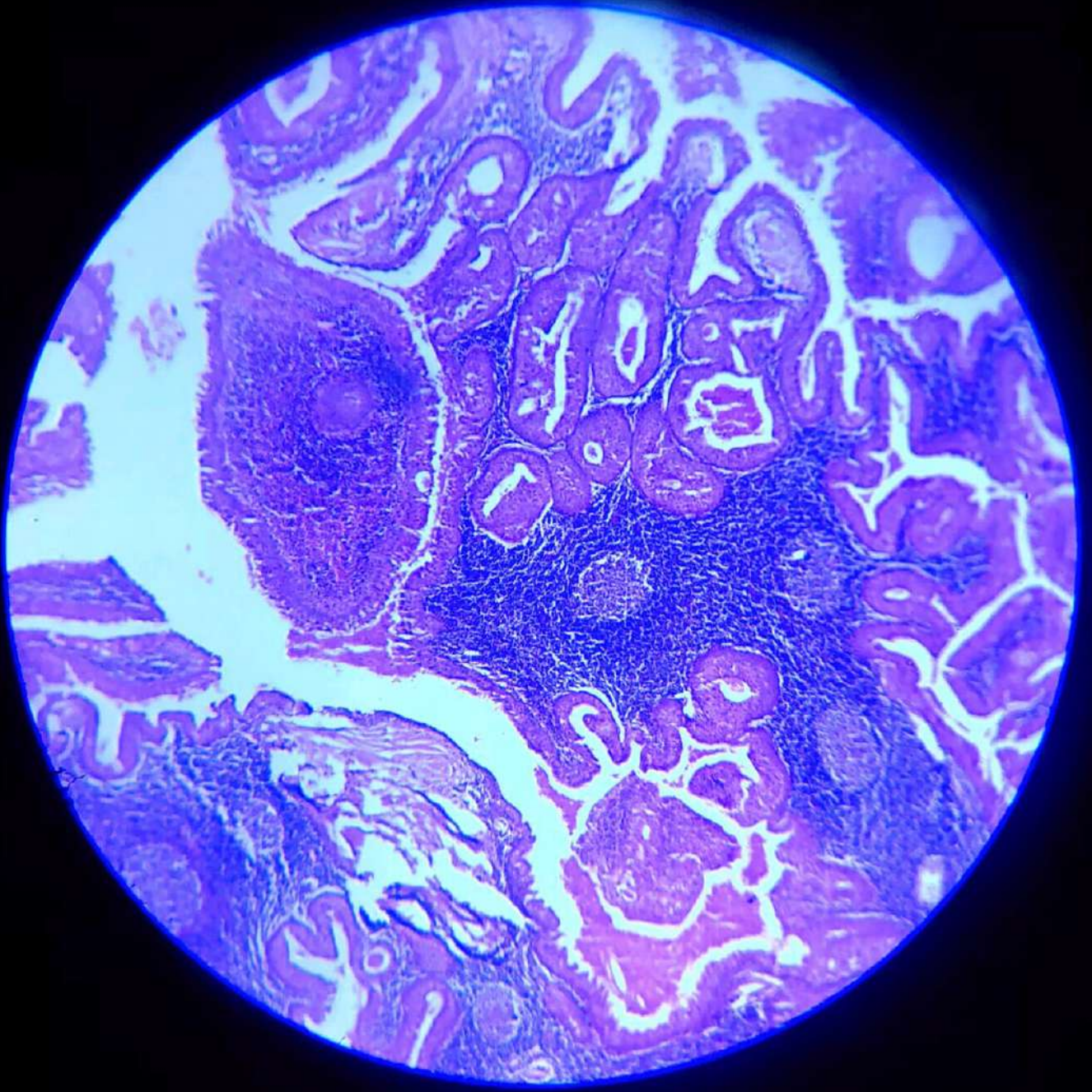
**Capillary Haemangioma**



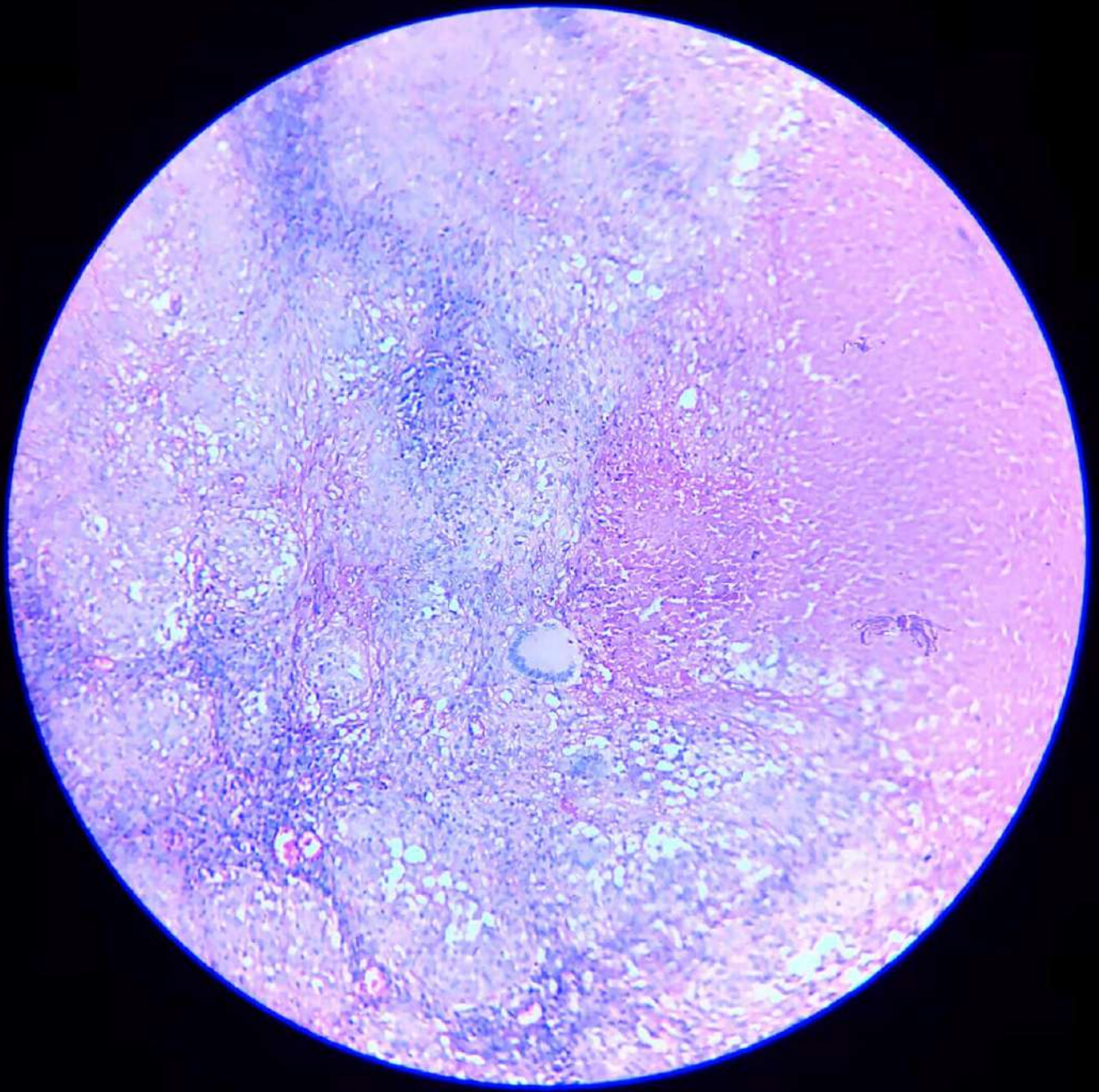
**Acute Appendicitis**



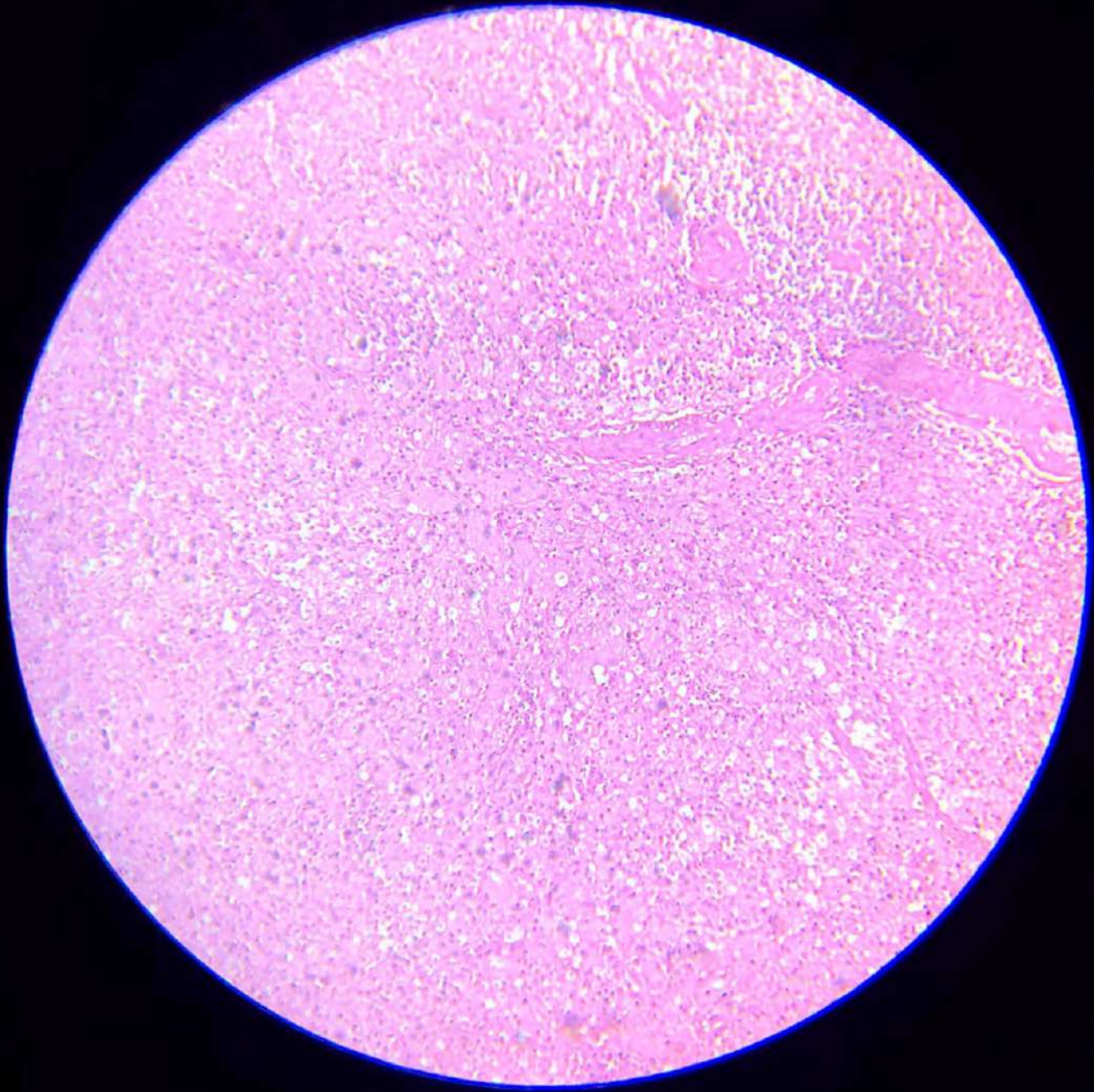
Fibroma



Warthin's Tumour

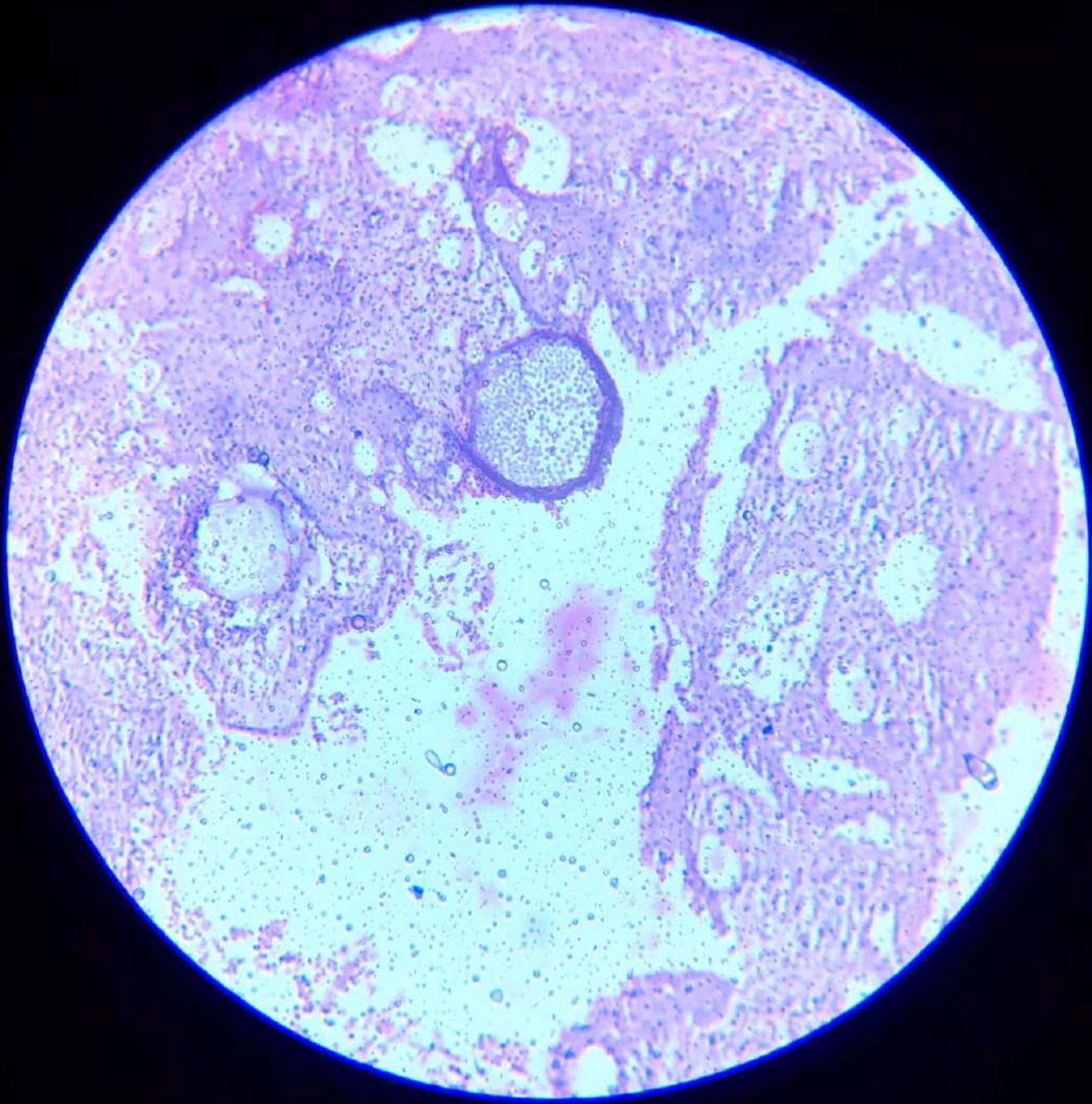


Tuberculous lymphadenitis

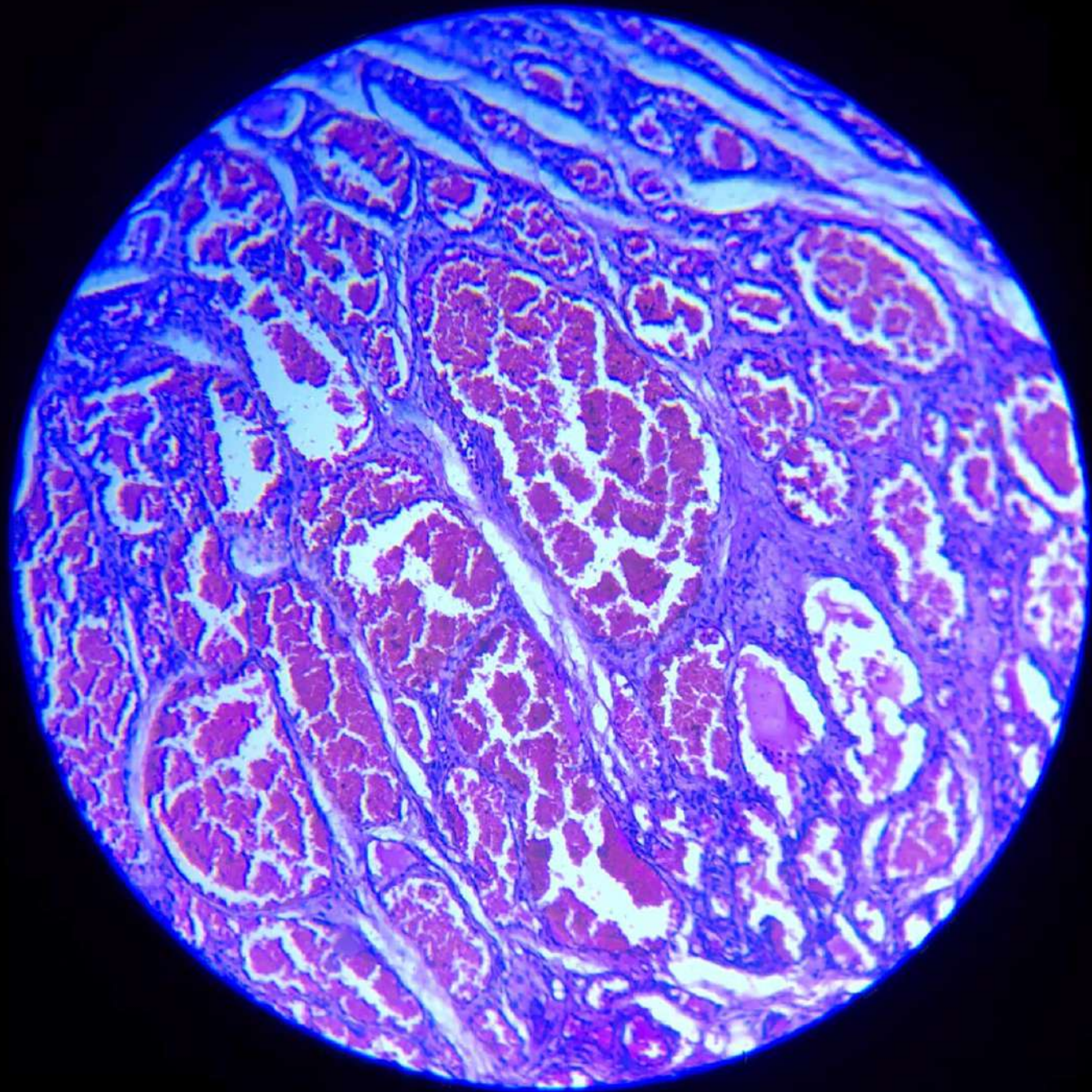


CVC Spleen

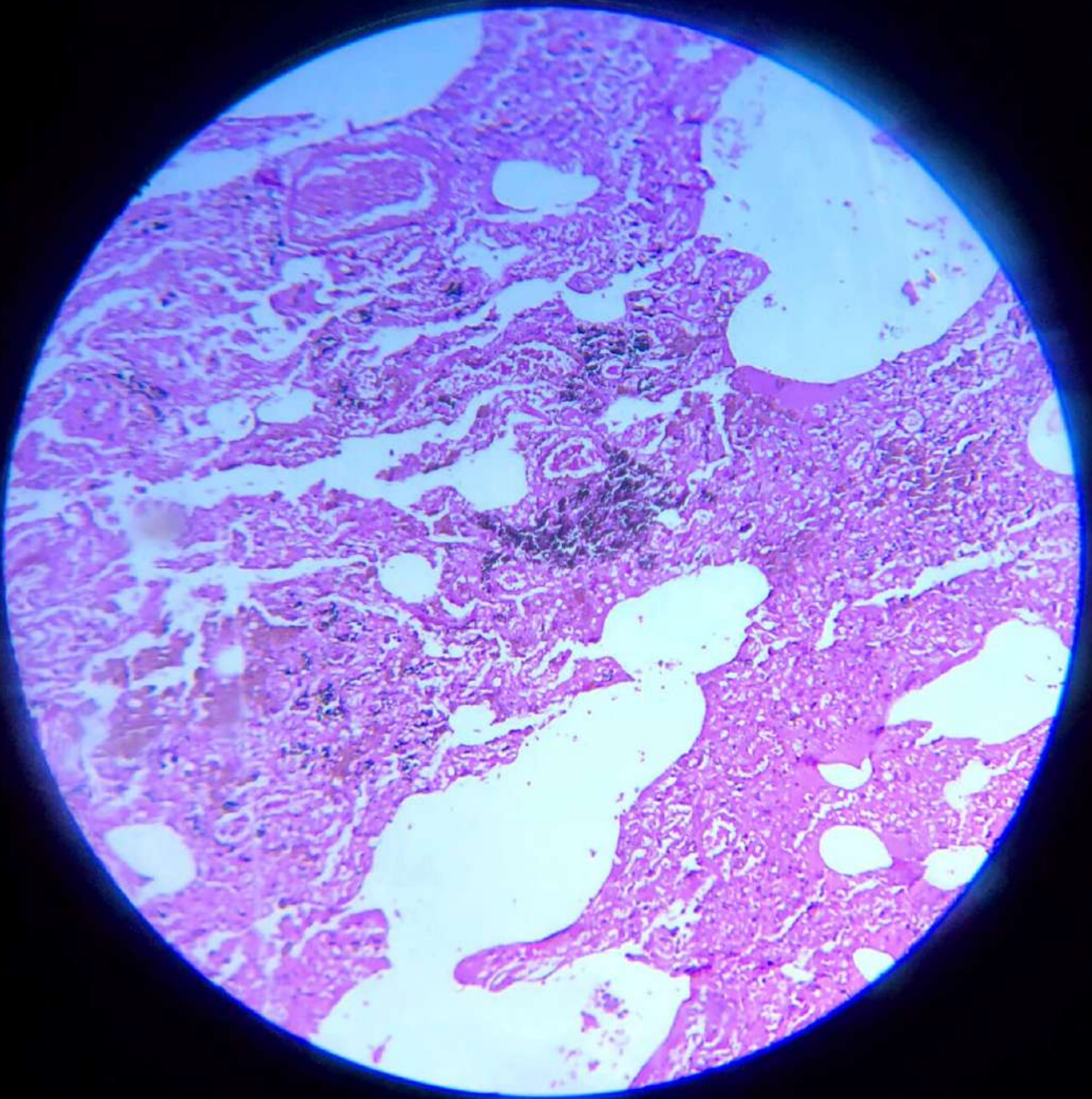
# Rhinosporidiosis

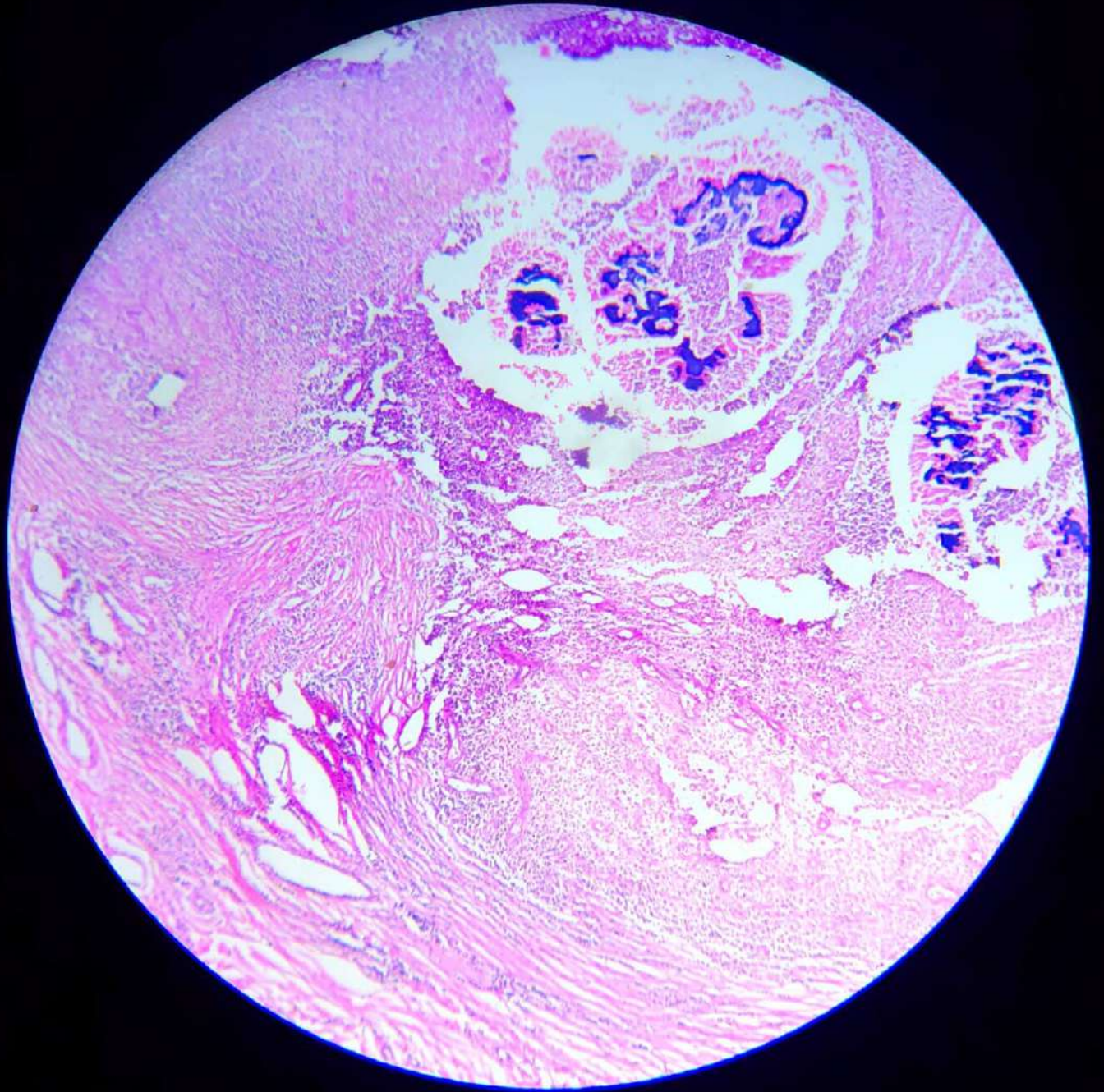


# Cavernous Haemangioma

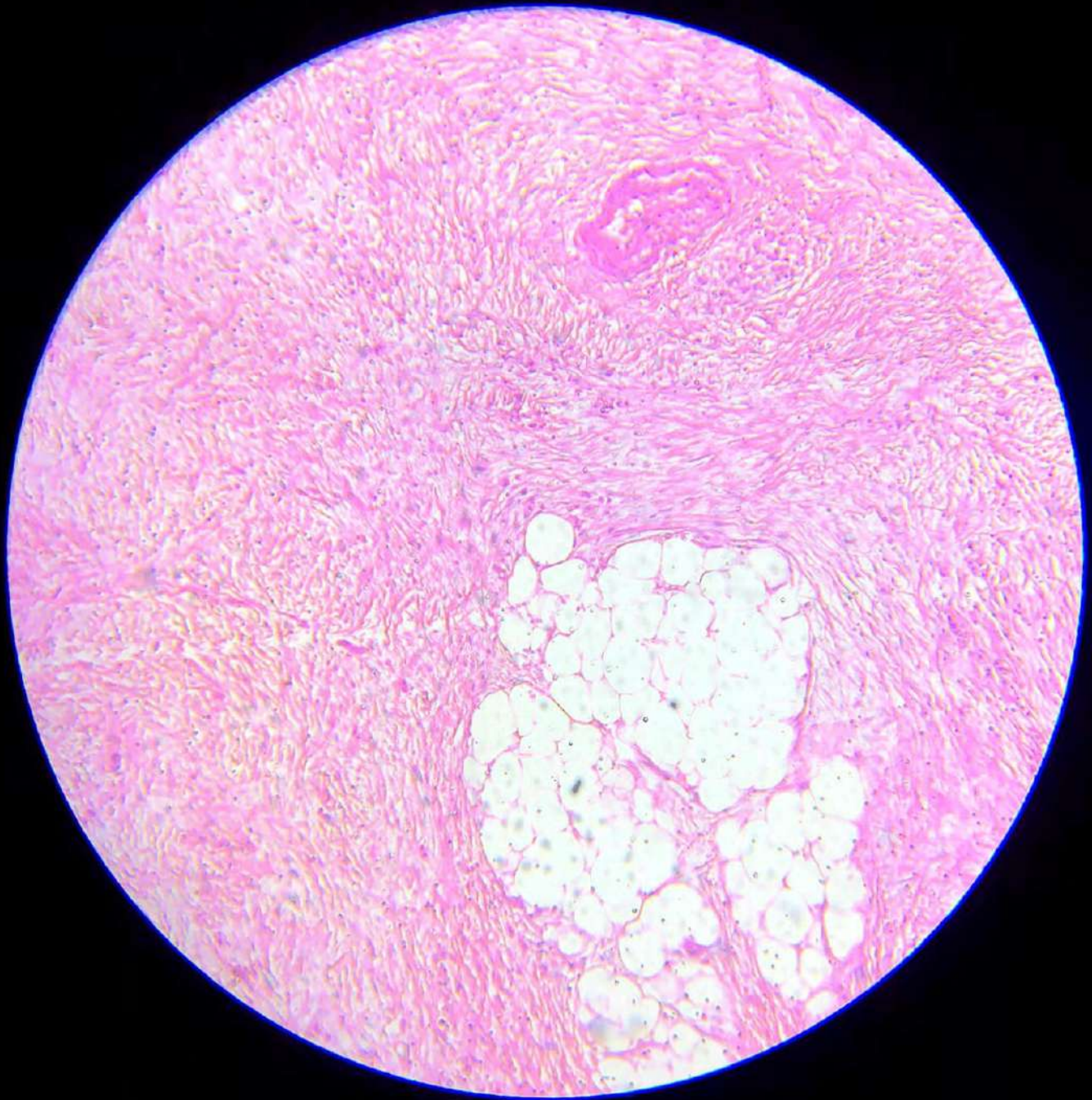


CVC lung

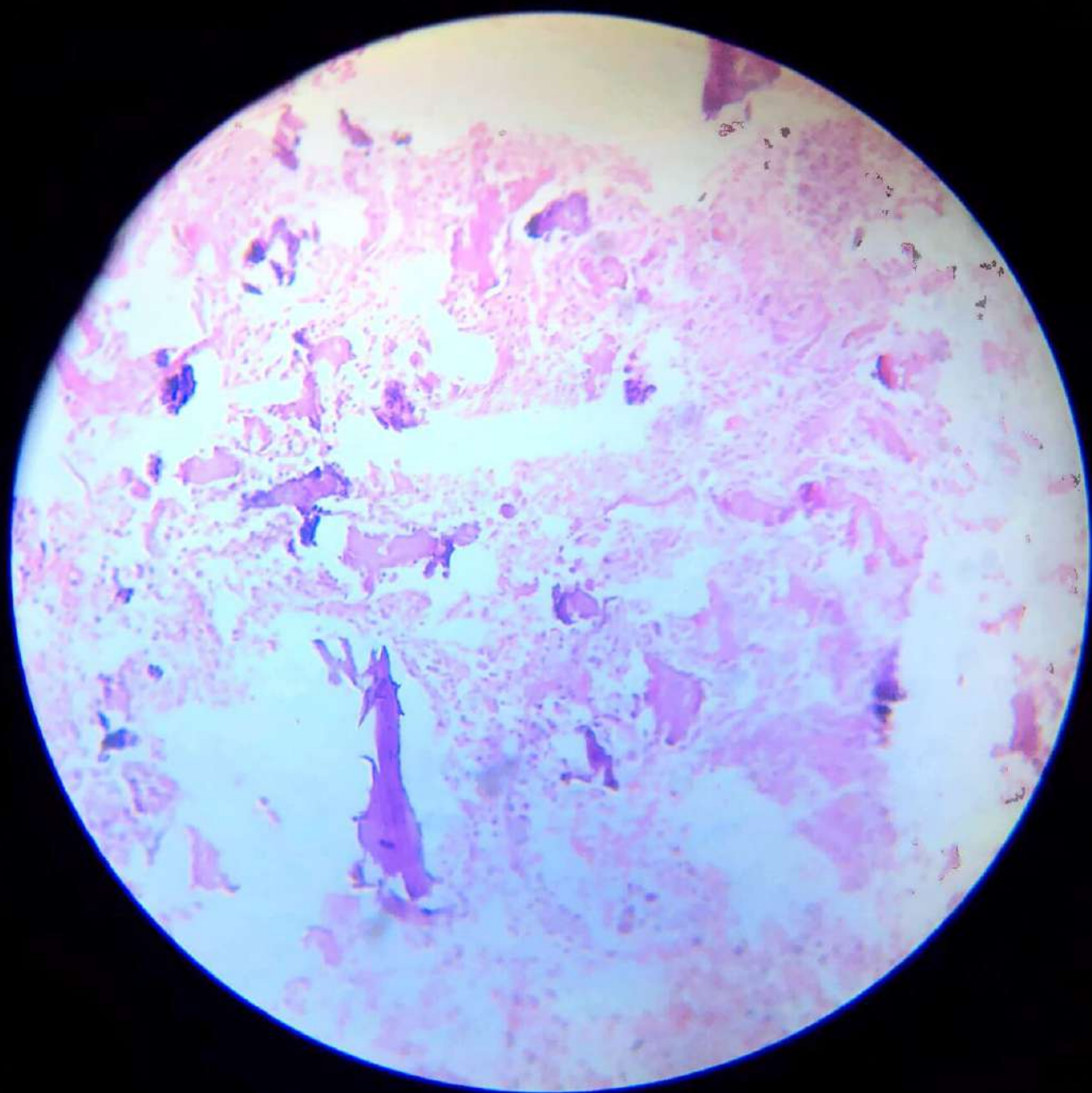




Actinomycosis



Adenocarcinoma



Osteosarcoma

# Osteoclastoma

